Laser und Licht ...

für die Netzhaut

Dr. med. Inga Kersten-Gomez

Universitäts-Augenklinik, Klin. Direktor: Univ.-Prof. Dr. med. HB Dick

© M. Elling u. I.Kersten-Gomez

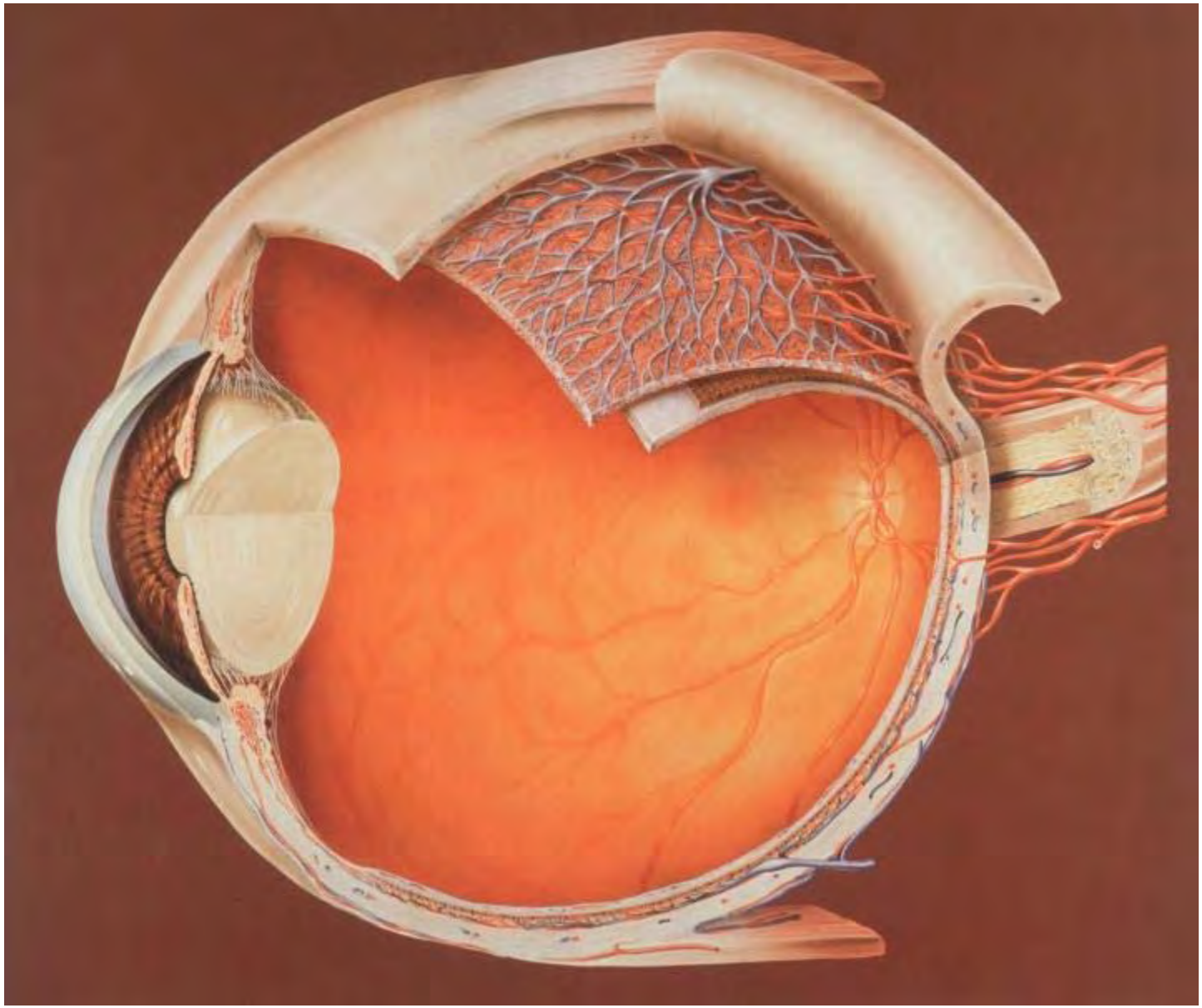

© M. Elling u. I.Kersten-Gomez

Laser
zur präzisen und frühzeitigen

→ Diagnose

© . I.Kersten-Gomez

Retinometer

- ***Rotes Laserlicht*** geringer Energie
- Abbildung eines Linienmusters auf der Netzhaut
- Trübungen von Hornhaut, Linse und Glaskörper stören nicht
- Überprüfung des ***Auflösungsvermögens der Netzhaut***, z.B. vor der Grauen-Star-OP

© M. Elling u. I.Kersten-Gomez

Retinometer

© M. Elling u. I.Kersten-Gomez

Nervenfaserschicht-Analyse (GDX)

- Vermessung der Nervenfaserschichtdicke
- Farbkodiertes Höhenprofil
- Abtastung durch Laserlicht

© I.Kersten-Gomez

OD Rechts

Q: 8 Benutzer:
H: 1489 µm V: 1768 µm
Datum: 16.02.09 16:49

OS Links

Q: 10 Benutzer:
H: 1582 µm V: 1875 µm
Datum: 16.02.09 16:46

Rechts Fundus Bild

TSNIT Parameter	OD	OS
TSNIT Durchschn.	53.8	53.4
Sup. Durchschn.	69.2	66.0
Inf. Durchschn.	59.9	65.6
TSNIT Std. Abw.	20.8	27.2
Augensymmetrie-Vergleich	0.93	
NFI	18	18

Links Fundus Bild

Rechts Nerven Faser-Schicht Dicke

p>=5% p<5% p<2% p<1% p<0.5%

Vorgeschichte Dicken-Karte (microns)

0 20 40 60 80 100 120 140 160 180 200

Links Nerven Faser-Schicht Dicke

Eindruck / Plan:

Unterschrift:_____ Datum:_____

Rechts Abweichungs Karte

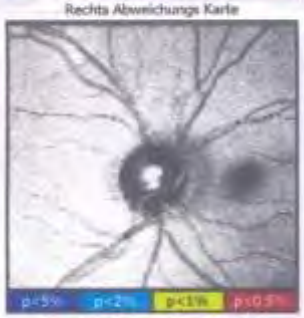

Links Abweichungs Karte

Rechts Nerven-Faser Schicht



Beide Nerven-Faser Schichten

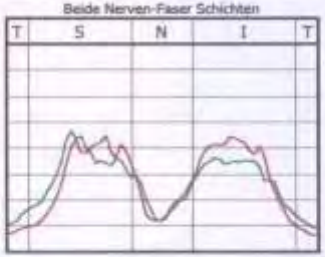

Links Nerven-Faser Schicht



© . I.Kersten-Gomez

Optische Kohärenztomographie (OCT)

- ***Schnittbild*** durch die Netzhaut

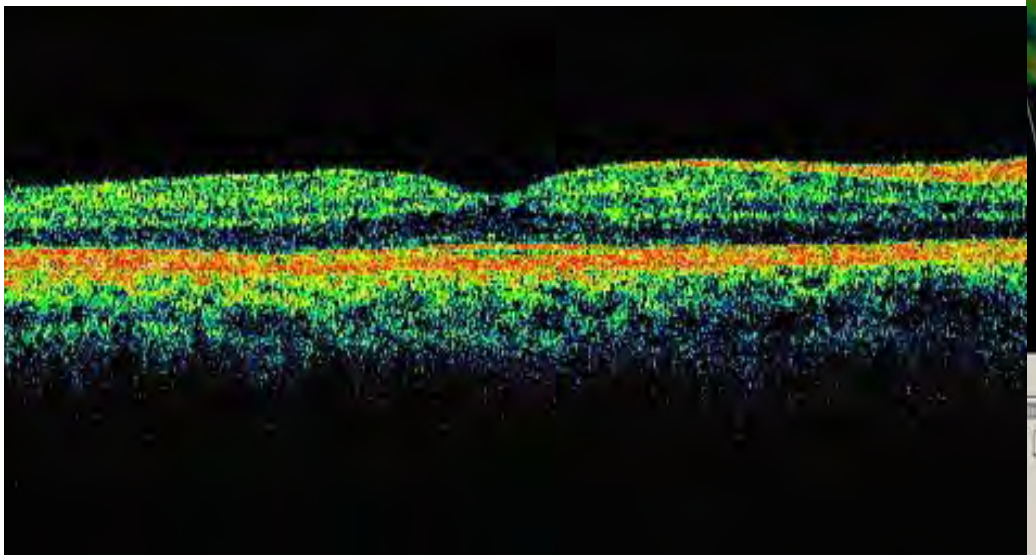

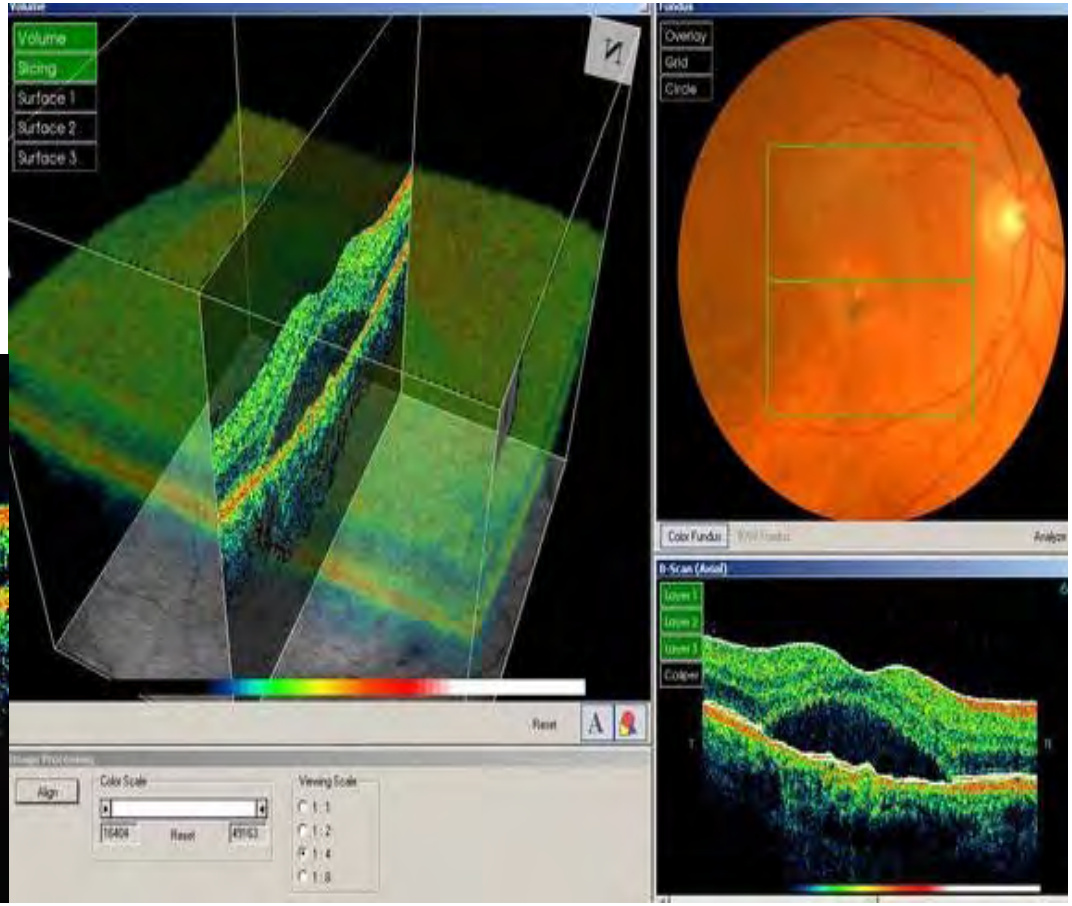

© M. Elling u. I.Kersten-Gomez

Darstellung des Sehnerven im SD-OCT

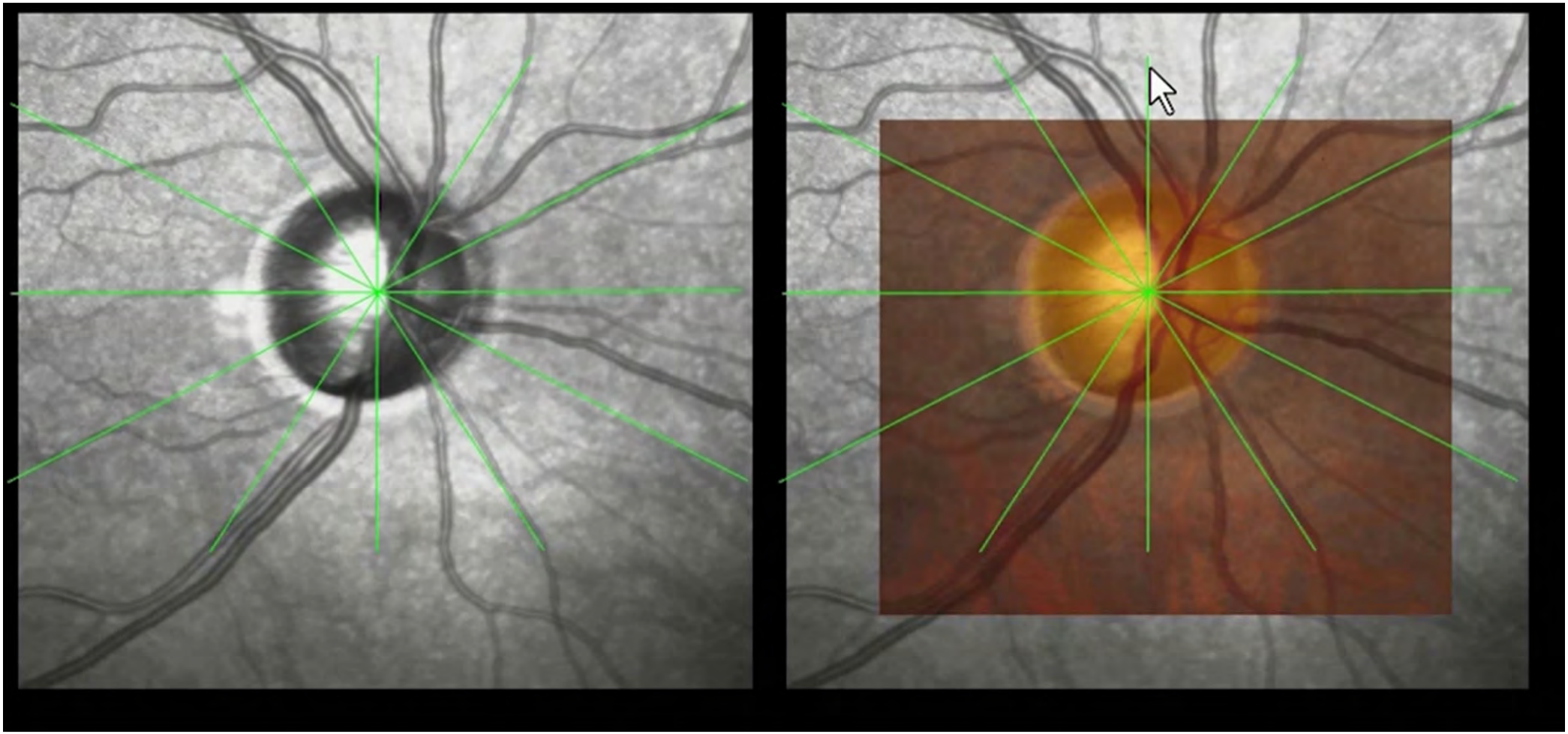

© M. I.Kersten-Gomez

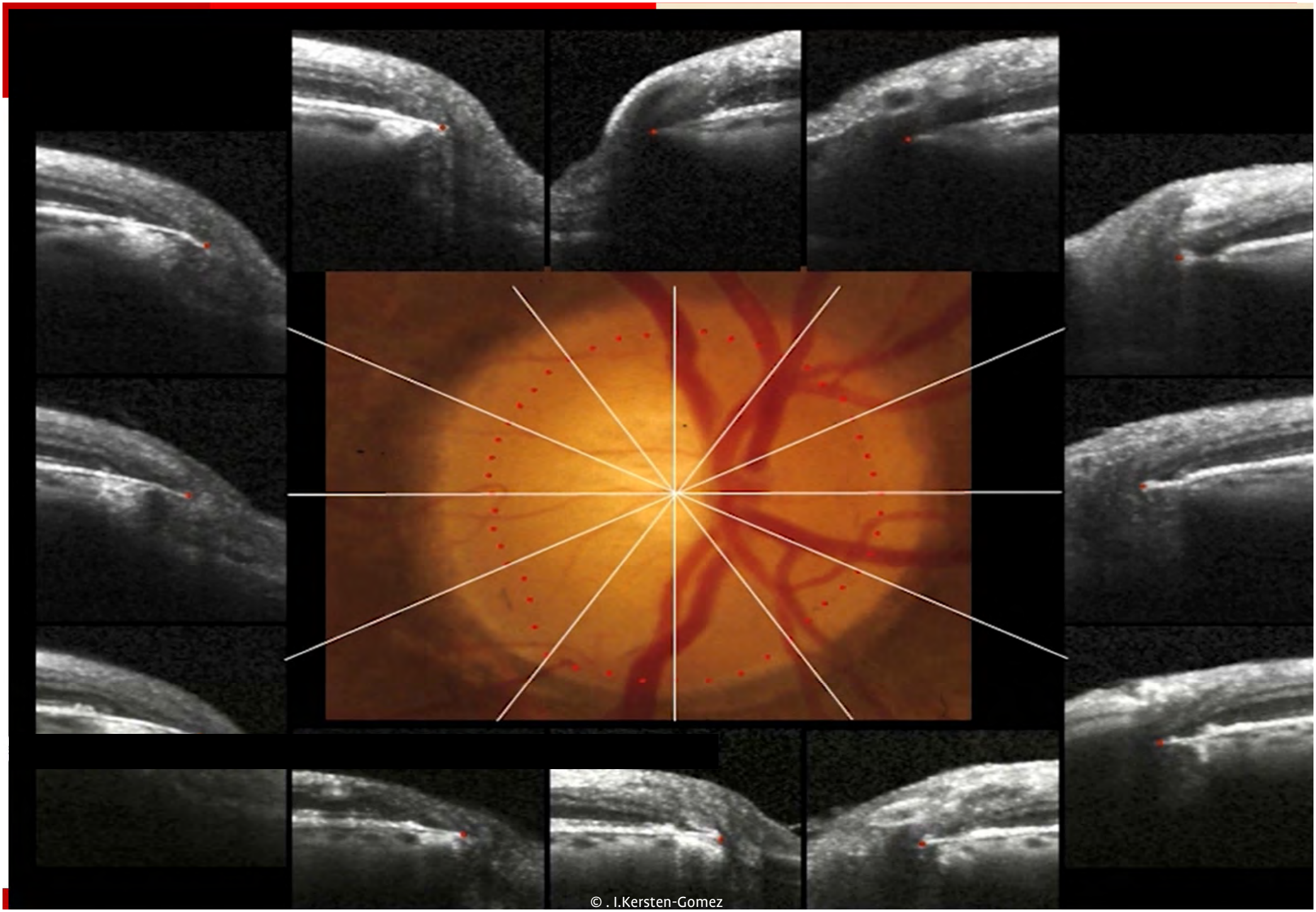
© . I.Kersten-Gomez

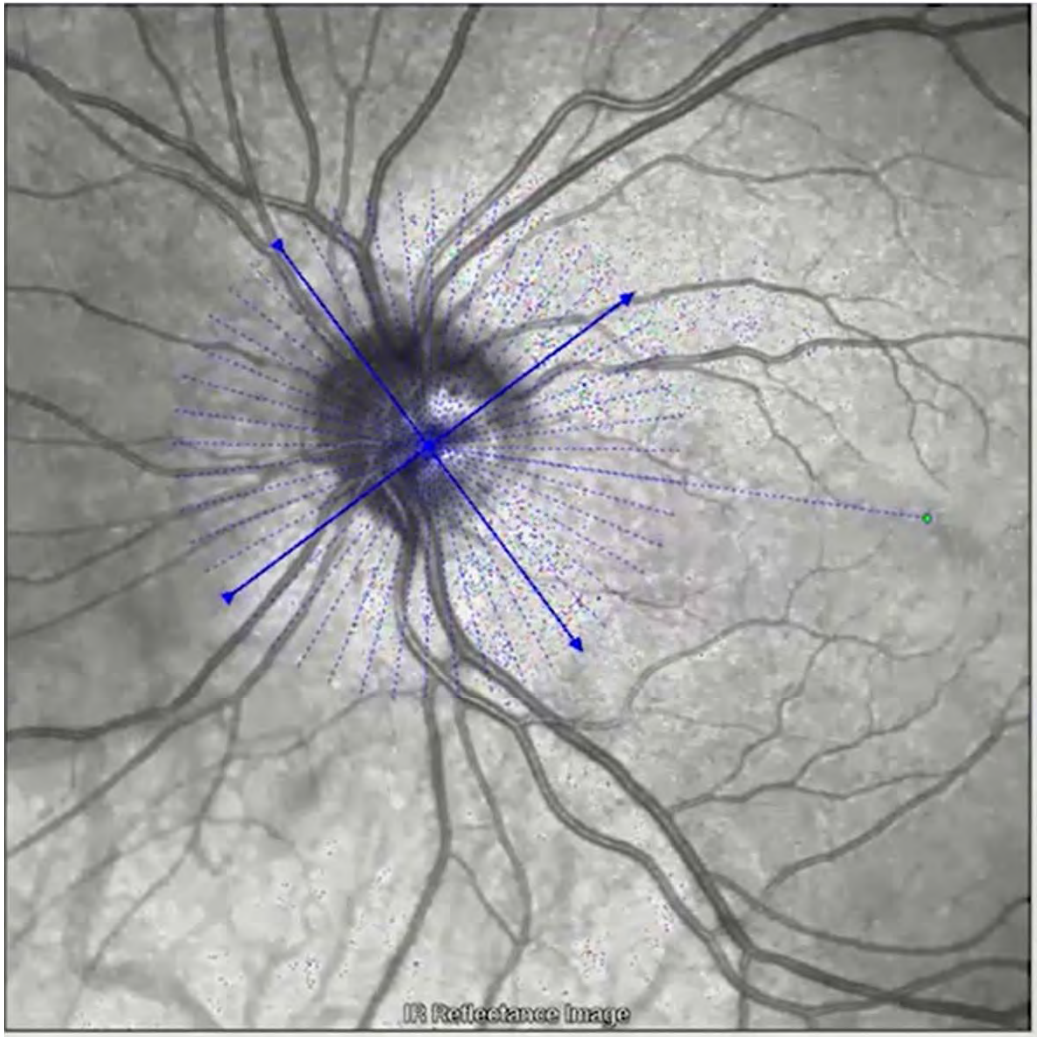
IR Reflectance Image

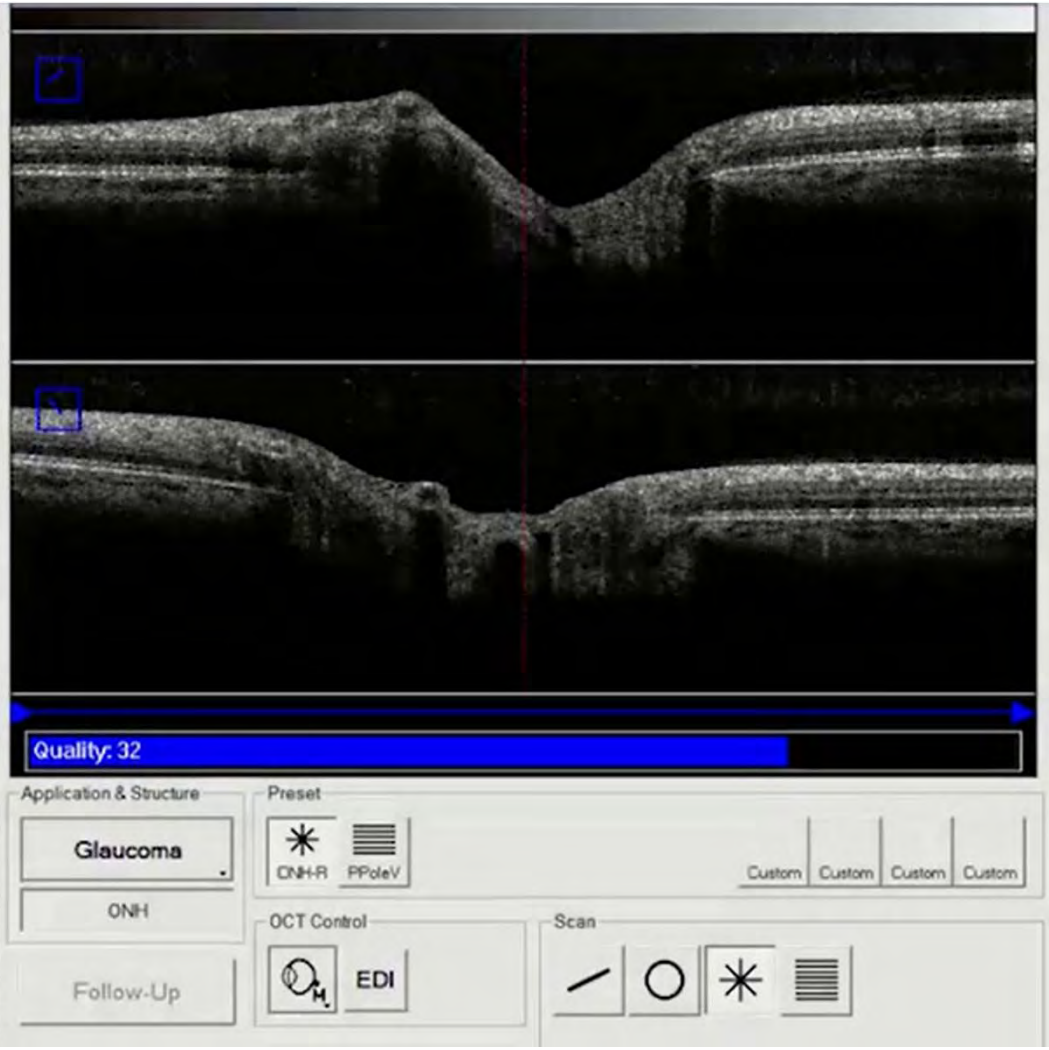
Quality: 32
Application & Structure
Glaucoma
ONH
Follow-Up
Preset
ONH-R
PPoleV
Custom
Custom
Custom
Custom
OCT Control
EDI
Scan

Darstellung der Macula im SD-OCT

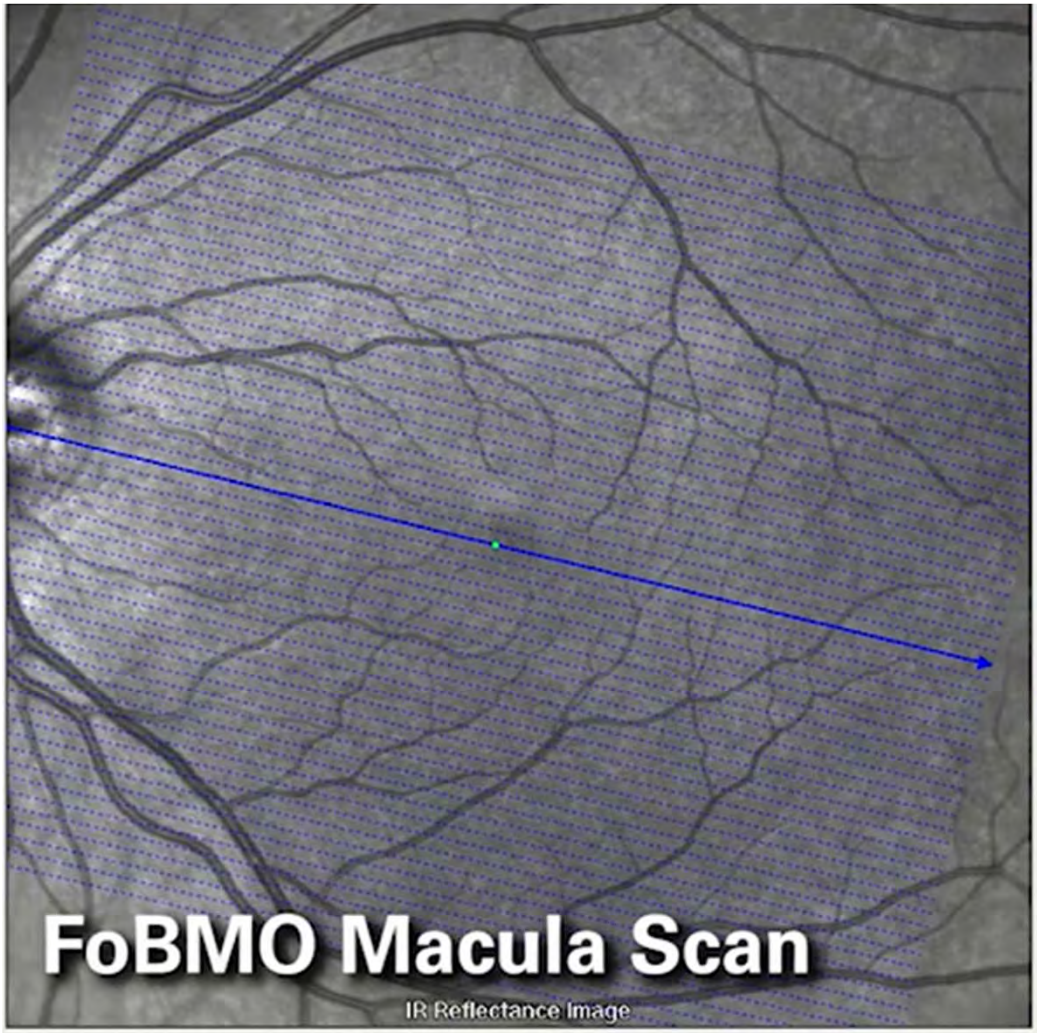

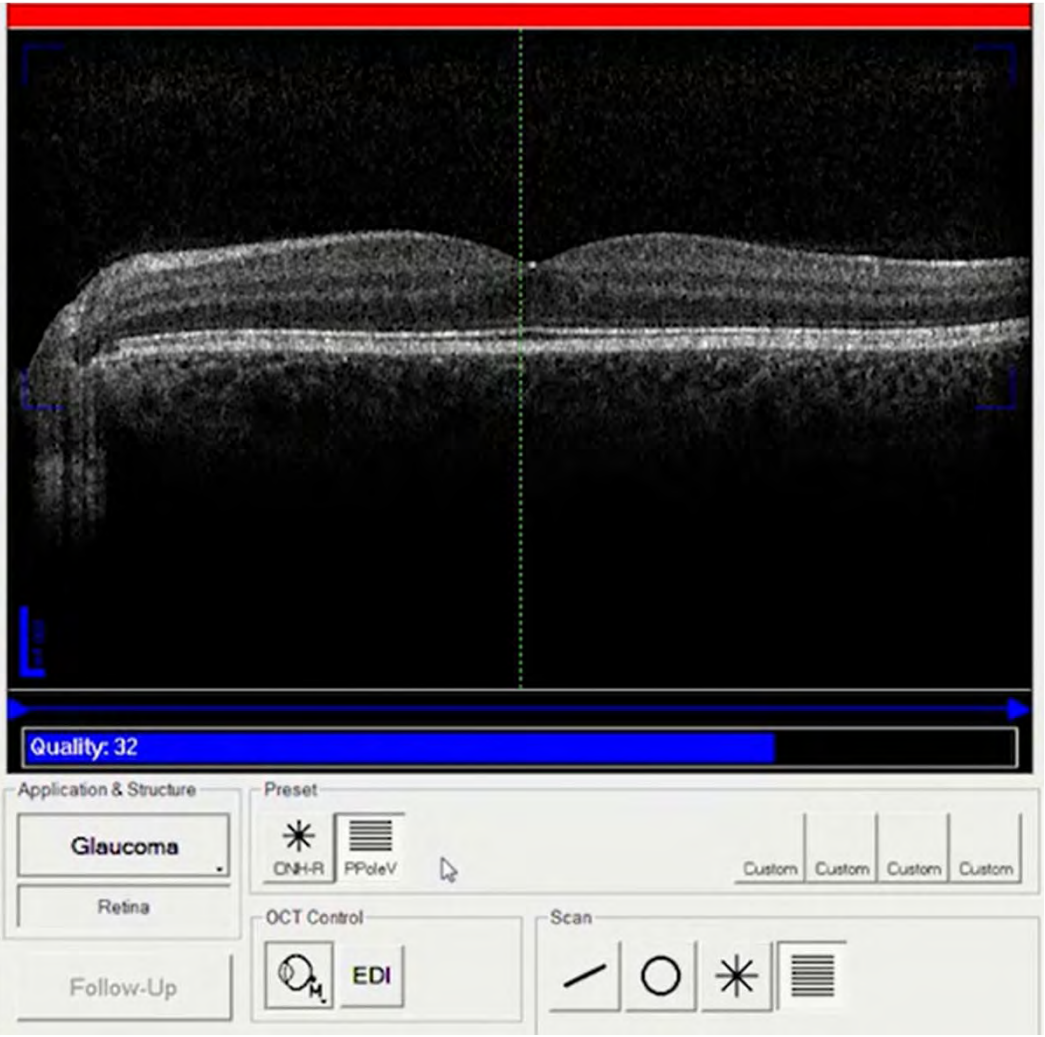

© . I.Kersten-Gomez

Laser zur gezielten

→ Therapie

Diabetische Retinopathie

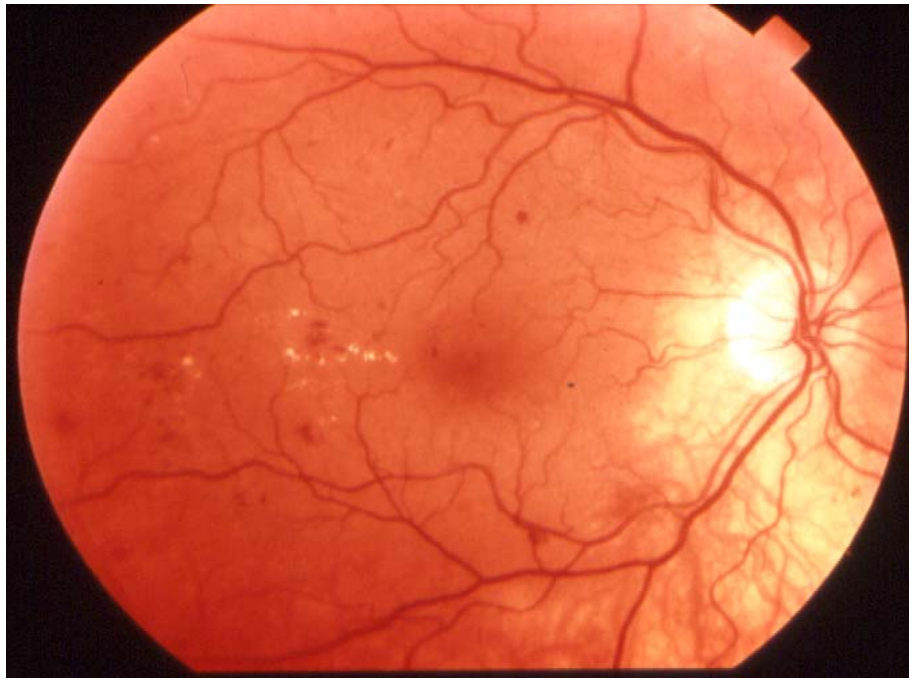

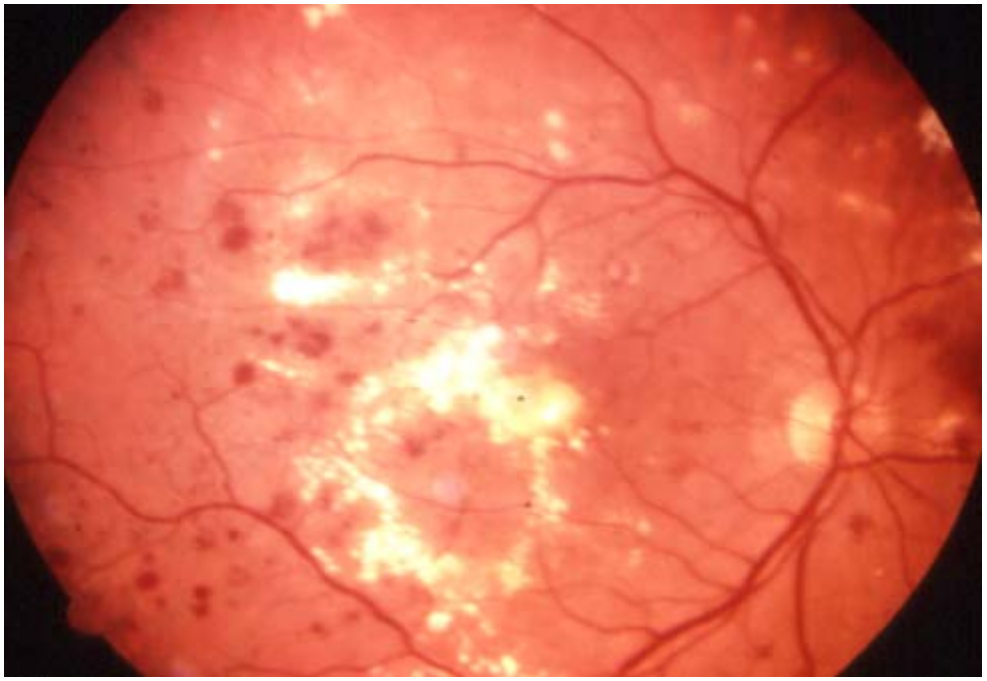

© M. Elling u. I.Kersten-Gomez

Lasertherapie

© M. Elling u. I.Kersten-Gomez

© I.Kersten-Gomez

CoCo bei grünem Star

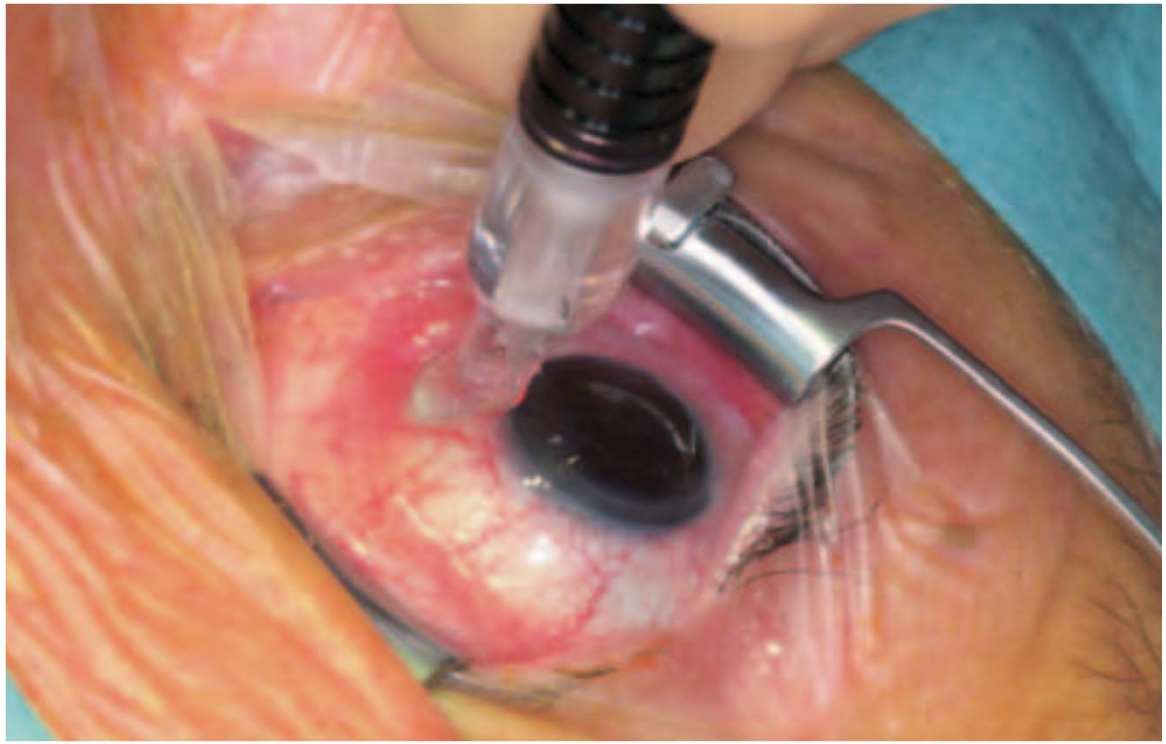

© M. Elling u. I.Kersten-Gomez

Netzhautloch / -riss

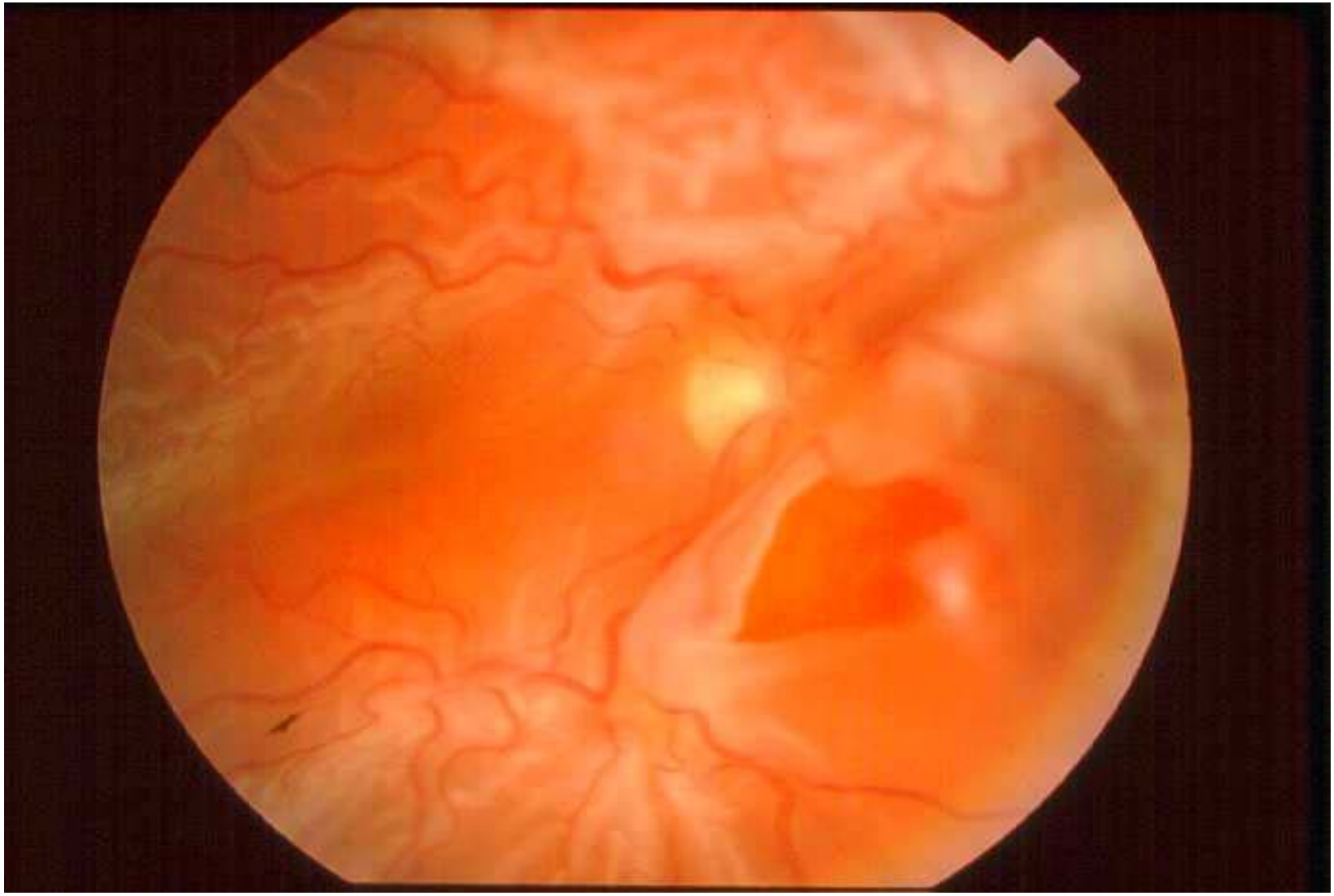

© M. Elling u. I.Kersten-Gomez

Lasertherapie des Netzhautloches

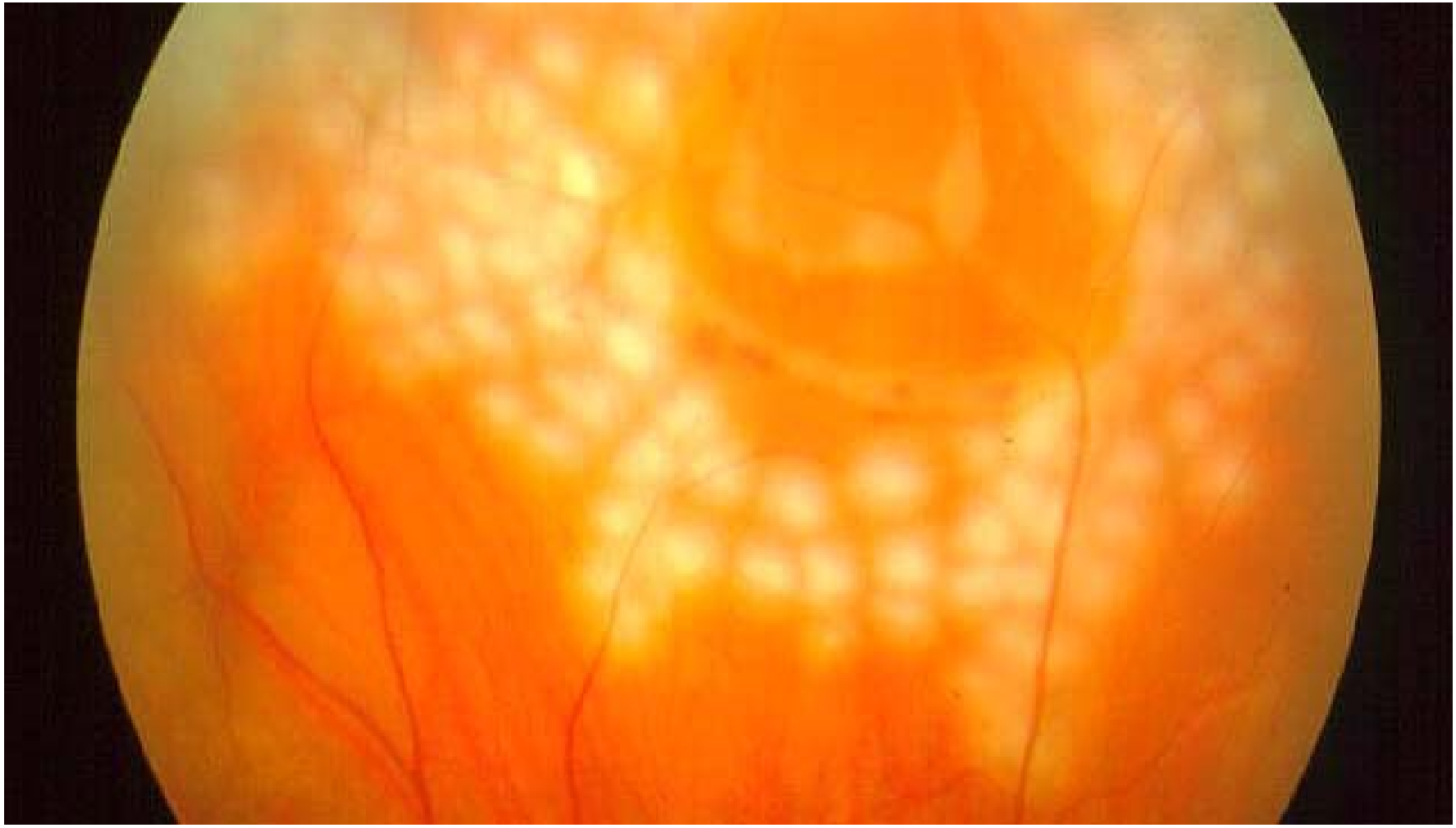

© M. Elling u. I.Kersten-Gomez

Vielen Dank !

© I.Kersten-Gomez